



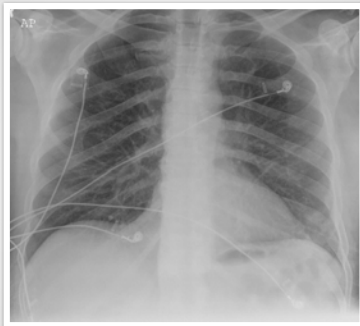
The pleura, diaphragms, and chest wall

The chest wall—common pathology

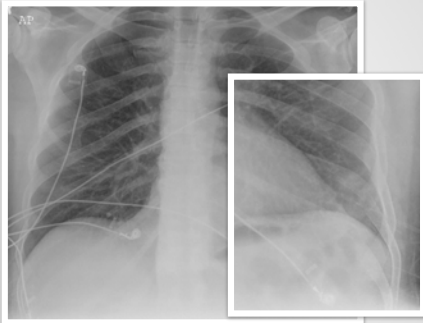
What will I gain from this video?

After watching this video, you will know how to search for and identify common pathologies involving the chest wall.

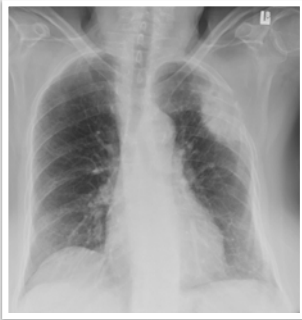Ribs



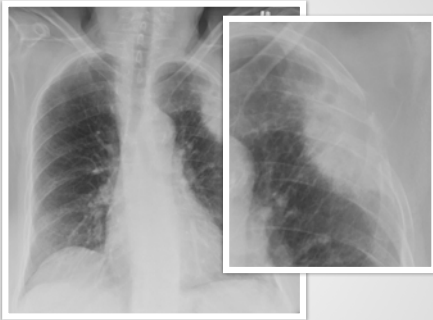Ribs



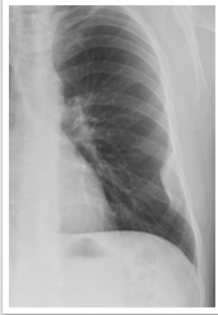Ribs



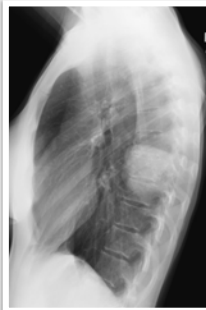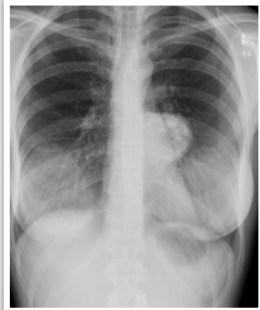
Ribs



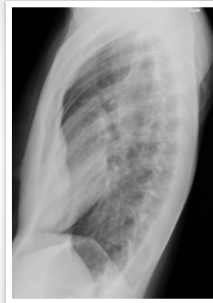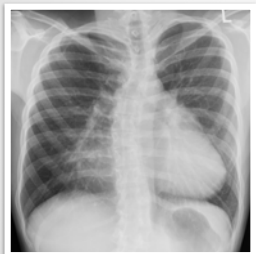Ribs



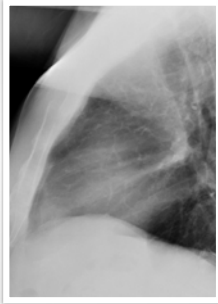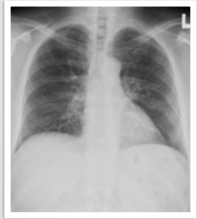Ribs



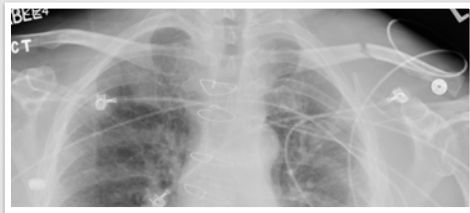Sternum



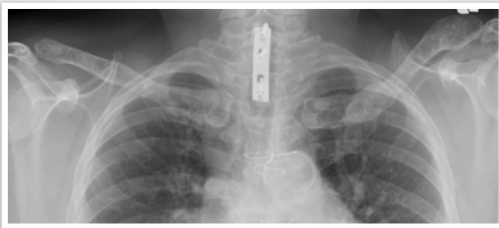
Sternum



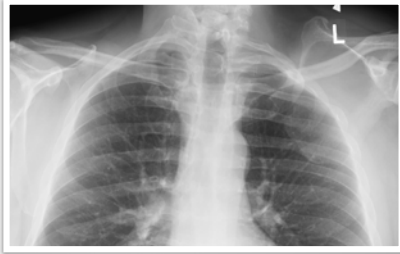Clavicles



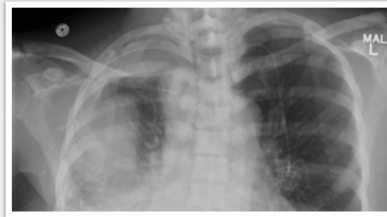Clavicles



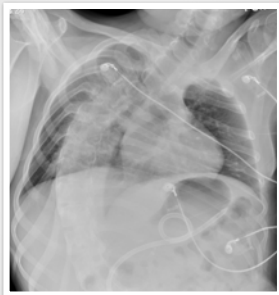Scapula



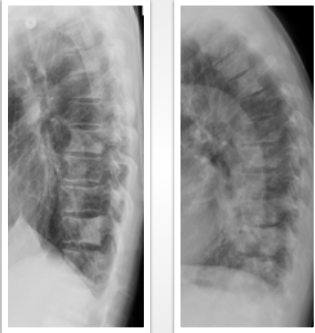
Scapula



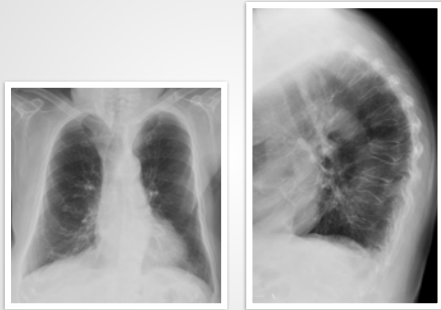
Spine



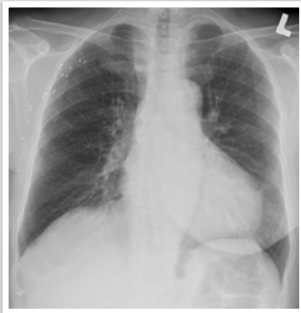Spine



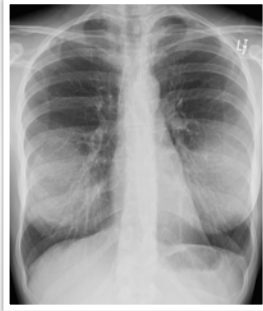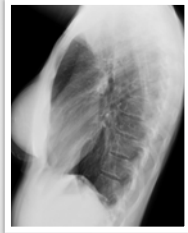Spine



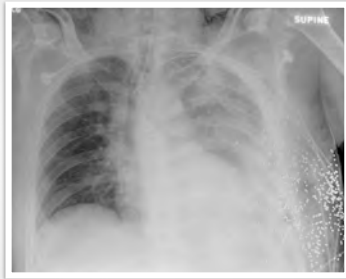Soft tissue



Soft tissue



Soft tissue



Use the magnifying glass.

Bone abnormalities are commonly missed.

Rib destruction means chest wall involvement.
